

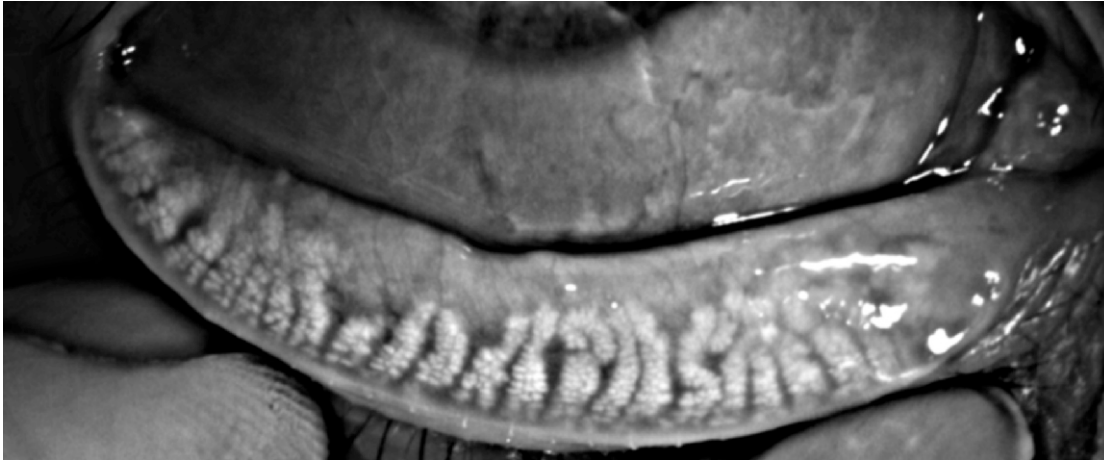

# SLM-6E(A) DRY EYE ANALYZER

Tear film imaging unit, specially designed for dry eye examination, exquisite and precise, no loss of nasal side ring image. Large aperture ensure images high definition and color rendition. Connected to optical system with hidden wire, more controllable and stable.

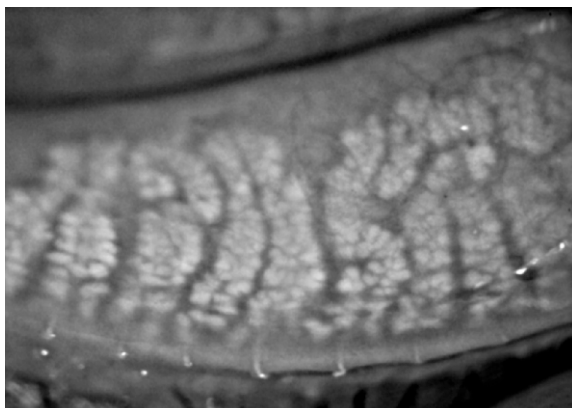
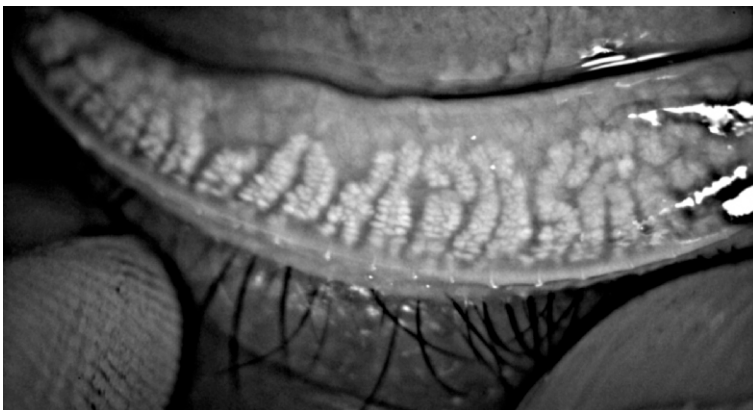# Meibomian gland function evaluation

Clear observation of meibomian glands Intuitively diagnose MGD



## Quantitative analysis of meibomian gland deletion

With infrared imaging system and HD digital camera, the area of meibomian gland deletion can be intuitively present. Meibomian gland loss severity can be objectively evaluated by comparing with the contrast models of meibomian gland deletion level.



## Multistep magnification observation of meibomian gland

Multistep optical magnification system support lossless image magnification. Meibomian gland distribution can be observed in the images of lower magnification, the area of missing glands can be clearly present. The detail of gland acini can be observed in the images of higher magnification, the outline is clear. It supports the clinicians to timely treat the meibomian gland lesions, diagnosis and treatment efficiency is improved.

Meibomian gland dysfunction(MGD) is the main cause of lipid layer deficiency, which leads to evaporative dry eye. It is characterized by obstruction of gland ducts, falling off the glands, or qualitative change and quantitative change of gland secretions. MGD results in tear film fast evaporation and hyperosmolarity, ocular surface inflammation, epithelium damage and discomfort.

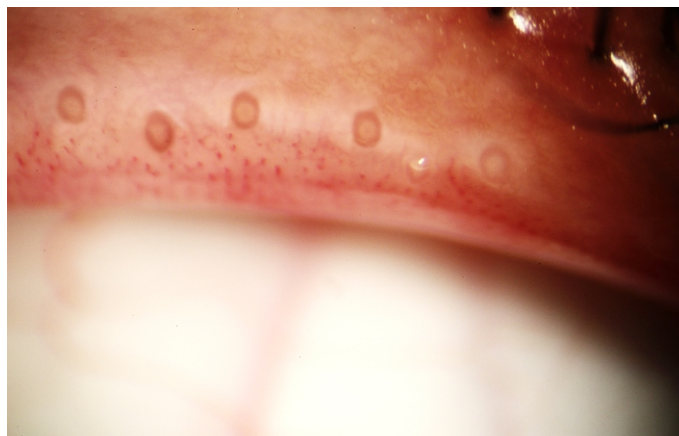
Infrared imaging is a fast and comfortable method of meibomian gland examination, which is the only non-invasive technology of observing meibomian gland in clinic.

SLM-6E(A) combines the infrared imaging technology, interference light measurement technology and multistep optical magnification technology. By taking HD images of meibomian gland and eyelid margin and dynamic video of lipid layer, the loss of meibomian gland is quantitatively classified, the eyelid margin and gland opening is intuitively observed, and the lipid layer is intuitively observed and graded. The meibomian gland function can be comprehensively analyzed accordingly, which can be the objective basis of dry eye main cause MGD diagnosis.

## Eyelid margin analysis

Eyelid margin change is one of the typical characters of MGD, including eyelid margin morphologic change and meibomian gland opening change.

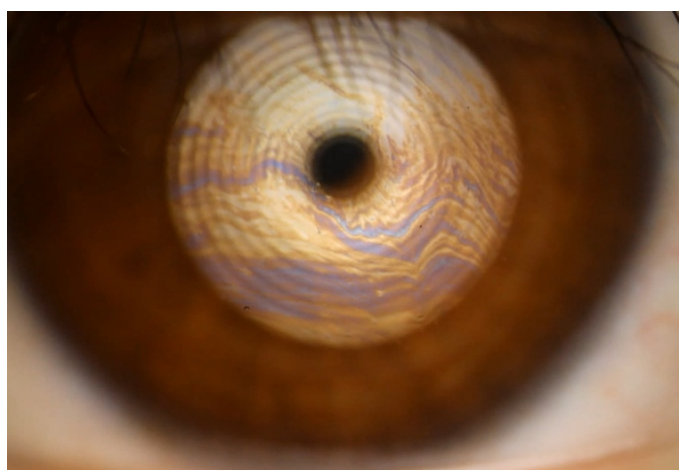
SLM-6E(A) has multistep optical magnification system, meeting the observation requirement of eyelid margin morphologic change and meibomian gland opening change. Meibomian gland and gland opening distribution can be observed in the images of lower magnification, the details of eyelid margin and gland opening change can be observed in the images of higher magnification. The images provide the intuitive diagnosis basis for eyelid margin abnormality or MGD.



## Lipid layer analysis


SLM-6E(A) analyzes the thickness, quality and quantity of lipid layer by comparing with graded contrast models, diagnose MGD combining with meibomian gland and eyelid margin analysis.

Specially designed tear film imaging unit enlarges the aperture and reduces the light loss, increase the image resolution and color rendition. The lipid layer morphology and coating process can be dynamically observed by HD videos, which have exquisite frame and strong hierarchical effect.



# Dry eye disease comprehensive examination

All-round examination items Comprehensive dry eye evaluation

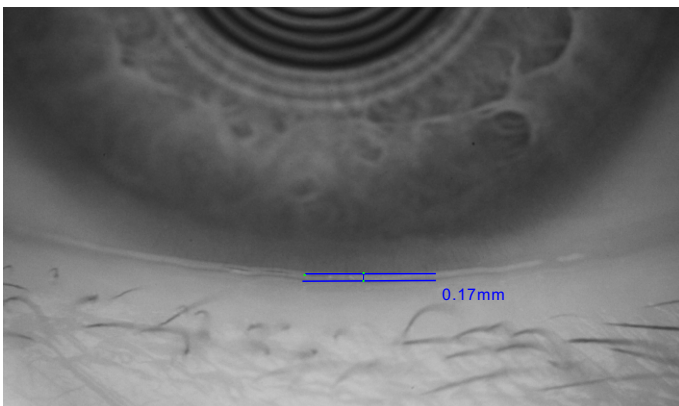


## Non-invasive break up time ( NIBUT)

Dry eye disease (DED) is characterized by tear film instability. SLM-KD3 quantitatively evaluates the state of tear film stability by identifying the ring image changes on the tear film.

Tear film imaging unit utilize the infrared light, which is non-invasive and non-stimulative. It directly face to the eye being examined, the ring image is complete and the nasal side ring image have no defect, which ensure the complete video record.

Compare with fluorescein staining, non-invasive examination provide more comfortable experience for the patients, automatic timing system is more accurate and efficient, and operation process is simplified.

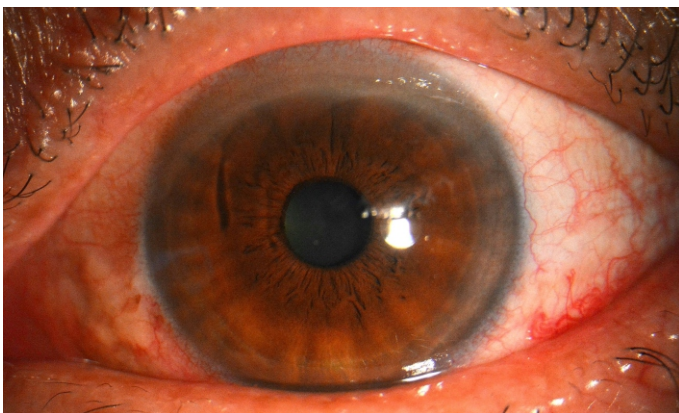


## Tear meniscus height (TMH)

Compare with Schirmer test, SLM-6E(A) shorten the examination time by more than 10 times, and the result is more accurate.

Tear film imaging unit utilize the infrared light, which is non-invasive and non-stimulative. Specially designed tear film imaging unit enlarges the aperture and reduces the light loss, increase the image resolution.


Multistep optical magnification system support image optical magnification for more detailed observation of tear meniscus morphology. If the tear meniscus is discontinuous or uneven, conjunctivochalasis (dry eye complication) or palpebral margin abnormal (MGD) can be simultaneously examined.



## Bulbar redness scan (R-scan)

Common bulbar redness include conjunctival congestion , ciliary congestion and mixed congestion, which probably caused by dry eye disease or conjunctive. In dry eye examination, bulbar redness is preferentially considered to be aqueous deficient dry eye (ADDE).

SLM-6E(A) capture images in high definition, automatically grade the conjunctival congestion and ciliary congestion and evaluate the severity of bulbar redness.



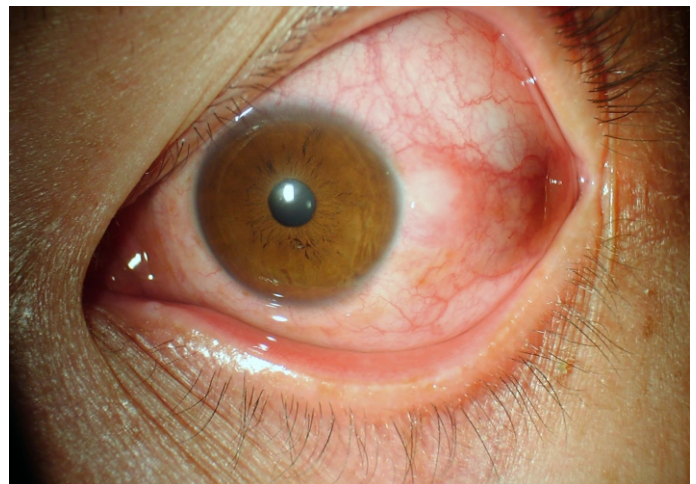
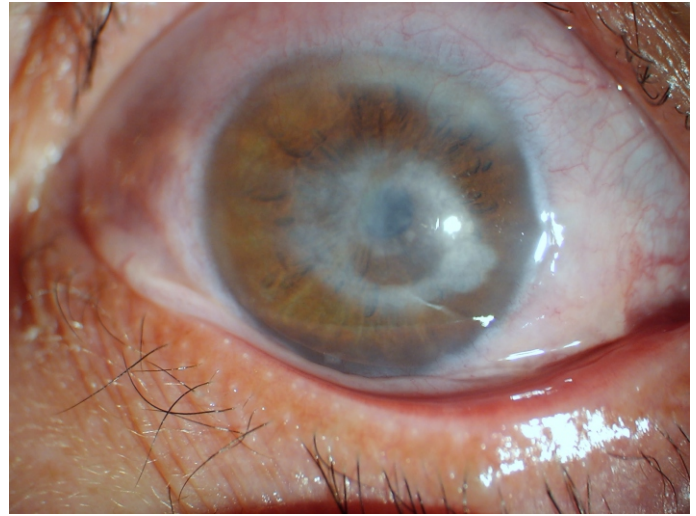
## Corneal staining

Assess the corneal epithelial completeness, check mucous deficient dry eye or corneal inflammation.

Unique optical magnification system support lossless image magnification. Five blue filter combinations enhance the effect of fluorescein staining, cornea details can be observed clearly, which spares no details of small corneal lesion.

# Anterior segment examination on same device

More practical function More efficient examination



## Dry eye complications examination

Without changing the device, dry eye complications can be rapidly checked, including cornea damage (cornea scarification, cornea inflammation, cornea ulcer, cornea perforation), corneal nebula, conjunctivochalasis, which improving the checking efficiency and patient's satisfaction.

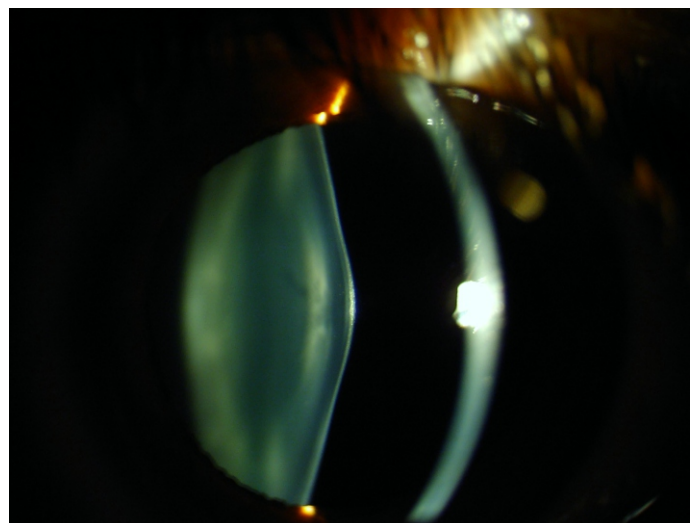
Binocular eyepiece for better observation with stereoscopic view. Multistep optical magnification system support lossless image magnification. Built-in contrast-enhanced filter for more clear observation of lesion detail.

## Anterior segment examination

All of anterior segment examinations can be done on same device, more efficient. Anterior segment examinations include but not limited to:

Ocular surface disease, measurement of cornea diameter and pupil diameter and lesion area, corneal lesions, lens lesions, 1/3 forepart of vitreous lesions.

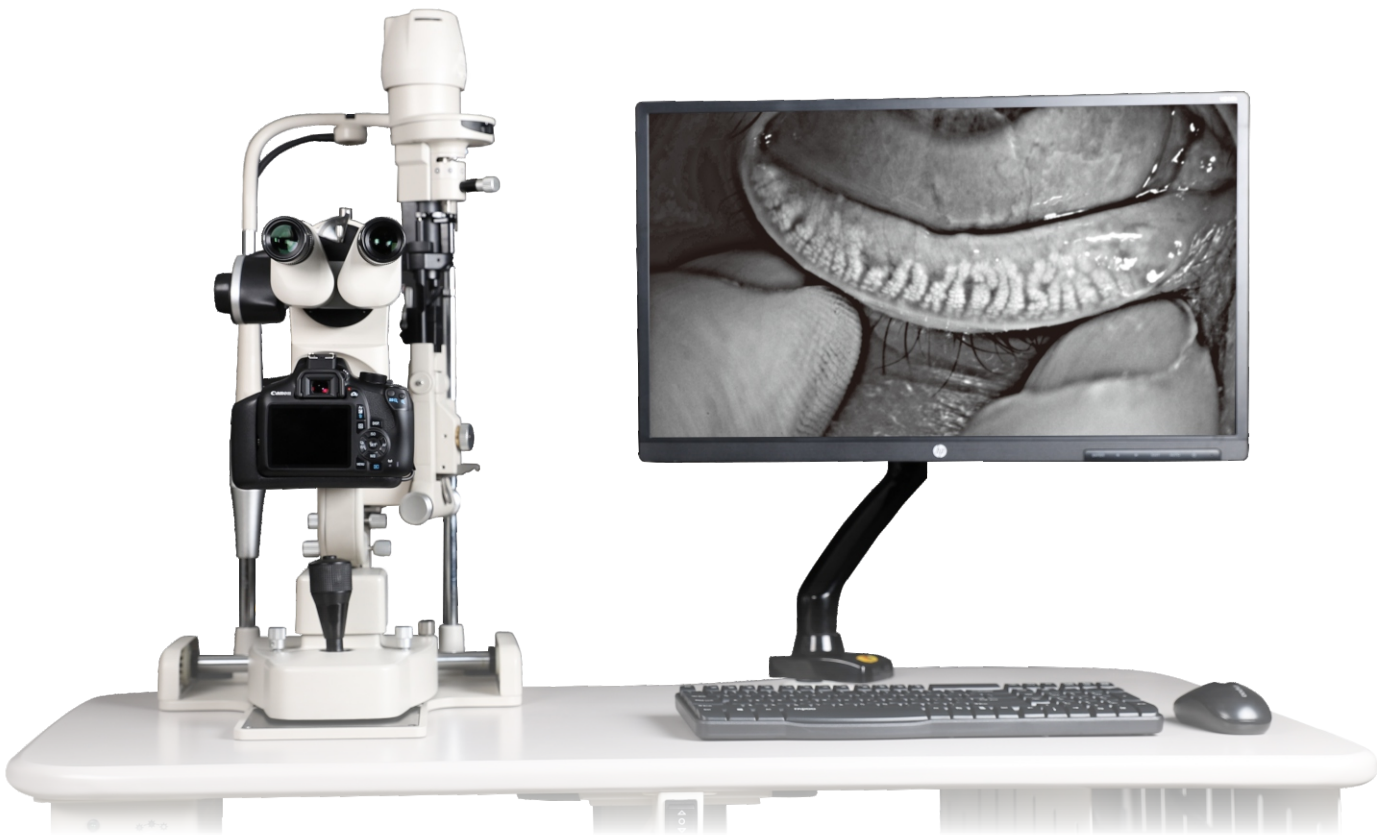
Examinations of the fundus and posterior segment of vitreous can be done with other additional accessories, corneal contact lens matching examination for identifying the contact lens contraindications.



# SLM-6E(A)

Objective analysis of dry eye disease  
Integrated comprehensive platform

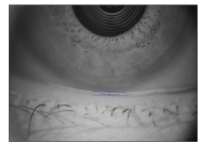

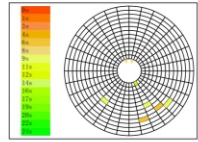
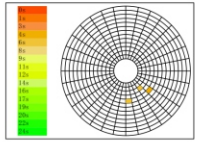
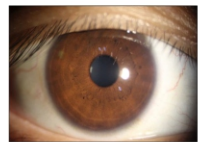
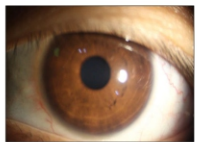


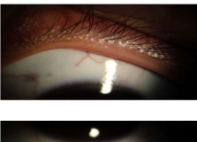

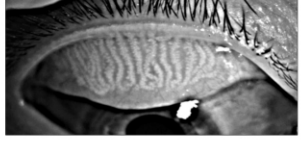
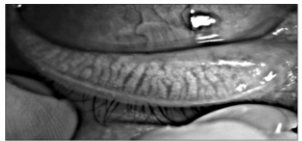
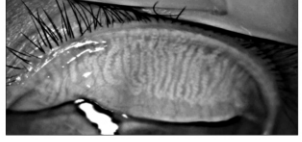
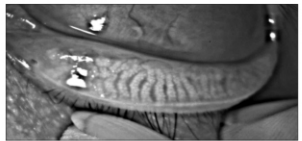
Tear film imaging unit, optical system, digital imaging system and precision mechanical platform be connected by hidden wires with special electronic technology, the device without external wire is more clean and tidy, avoid the malfunctions caused by twisted or damaged wires, improve the operation continuity and precision.



# Comprehensive analysis report

Automatically generate reports Full presentation of results

Automatically generate reports\* according to the examination results without manually filling in. illustrated report is easy to understand, operation process is simpler. Visible and intuitive report facilitate communication with patients.

Comprehensive Analysis Report			
Name: KH Sex: Male Age: 20 ExamID: 20190729004S Date: 2019/7/29 12:28:08			
	<b>R</b>	<b>L</b>	<b>Reference value</b>
<b>TMH</b>			R: 0.24mm                      L: 0.25mm  Reference: Infrared >= 0.2mm Visible >= 0.3mm
<b>NIBUT</b>			R:Breakup(1st): 7.60s                      Breakup(avg.): 9.40s Observation time: 13.20s L:Breakup(1st): 5.70s                      Breakup(avg.): 6.00s Observation time: 8.90s  Reference Level 0 Normal, Breakup(1st): 10 s, Breakup(avg.): 14 s. Level 1 Critical, Breakup(1st): 6-9 s, Breakup(avg.): 7-13 s. Level 2 Dry eye, Breakup(1st): 5 s, Breakup(avg.): 7 s.
<b>Lipid layer</b>	<b>Level: 4</b>	<b>Level: 4</b>	Reference: Level 1:<15nm Level 2:=15nm Level 3:=30nm Level 4:[30-80nm] Level 5:=80nm Level 6:[80-120nm] Level 7:[120-160nm]
<b>R-Scan</b>			R: <b>Conjunctival level:</b> 1.24 <b>Ciliary level:</b> 1.19  L: <b>Conjunctival level:</b> 1.52 <b>Ciliary level:</b> 1.70  Reference: <=2 Normal >2 Abnormal
<b>Gland opening</b>	 	 	R: <b>Upper:</b> Normal <b>Nether:</b> Normal  L: <b>Upper:</b> Normal <b>Nether:</b> Normal  Reference: gland openings 4 levels 1.Normal: blepharon is clear and transparent 2.Mild: gland openings bulge 3.Moderate: Eyelid margin of mucous membrane disappear and cornification 4.Severe: Eyelid irregularity,gland opening disappear,new vessels
<b>MGD</b>	 	 	R: <b>Upper:</b> 0.40                      L: <b>Upper:</b> 0.70 <b>Nether:</b> 0.50 <b>Nether:</b> 0.40  Reference: score 0: Normal score 1: Loss <= 1/3 score 2: Loss 1/3-2/3 score 3: Loss > 2/3
Doctor: 2019-07-29 12:35			

\* Comprehensive report provides all-sided results, and itemized reports present detailed images.

Dry eye	Placido ring (23 rings)	
	Tear meniscus height measurement	Visible light or infrared light selectable, optical magnification
	NIBUT	Visible light or infrared light selectable, duration $\leq 25$ sec, auto calculate the first break up time and average break up time
	Lipid layer grade evaluation	Grade with contrast models, measure lipid layer thickness
	Quantitative analysis of meibomian gland deletion	Imaging with infrared, quantitative analysis of deletion, optical magnification
	Eyelid margin analysis	Gland opening grading, optical magnification
	Bulbar redness analysis	Auto grading conjunctival congestion and siliary congestion severity
Optics	Resolution 1800•N lp/mm	
	High sensitivity	
	High-point eyepiece	
	Magnification 6.3× 10× 16× 25× 40×	
Illumination	LED (white/infrared)	
	Slit width 0~14mm	
	Slit length 1~14mm	
	Slit angle 0°~180°	
	Inclination 5° 10° 15° 20°	
	Aperture diameter $\Phi 0.2\sim 14$ mm	
	Colorless/ Heat absorption/ Grey/ Redfree/ Cobalt blue	
	Five blue filter combinations	
Digital	Contrast-enhanced filter	
	1800 Megapixel DSLR camera	
	Auto exposure	
	Auto optimization	
	Auto eye position identification	
	Coaxial background light	
Others	1080P Video	
	Dry eye complications examination	
	Anterior segment examination	

## Chongqing Kanghua Ruiming S&T Co.,Ltd.

Add: No.5, Road 1, Tongjiayi Industrial Park, Beibei, Chongqing, China

Service hotline: +86-23-63227333

Zip code: 400700

E-mail: kanghuaa@kanghuaa.com

Web: www.kanghuaa.com



Company website

**WE MAKE VISION MORE WONDERFUL**